Classification of Histopathology Tissue Images

Using Traditional Machine Learning and Convolutional Neural Networks.

MSc Health Data Science, University of Manchester

Methods

Dataset: The assignment dataset consists 55,490 training images and 4,367 test images of haematoxylin and eosin (H&E) stained colorectal tissue, each 28×28 pixels with three RGB colour channels. Images are labelled across five tissue classes: adipose, lymphocytes, normal colon mucosa, cancer-associated stroma, and colorectal adenocarcinoma epithelium. The training and test sets are derieved from different spatial locations within the tissue, which means the test images has a variation from the training images. The class distribution is slightly imbalanced, with cancer epithelium at 25.8% and normal mucosa at 15.8% (Figure 1).

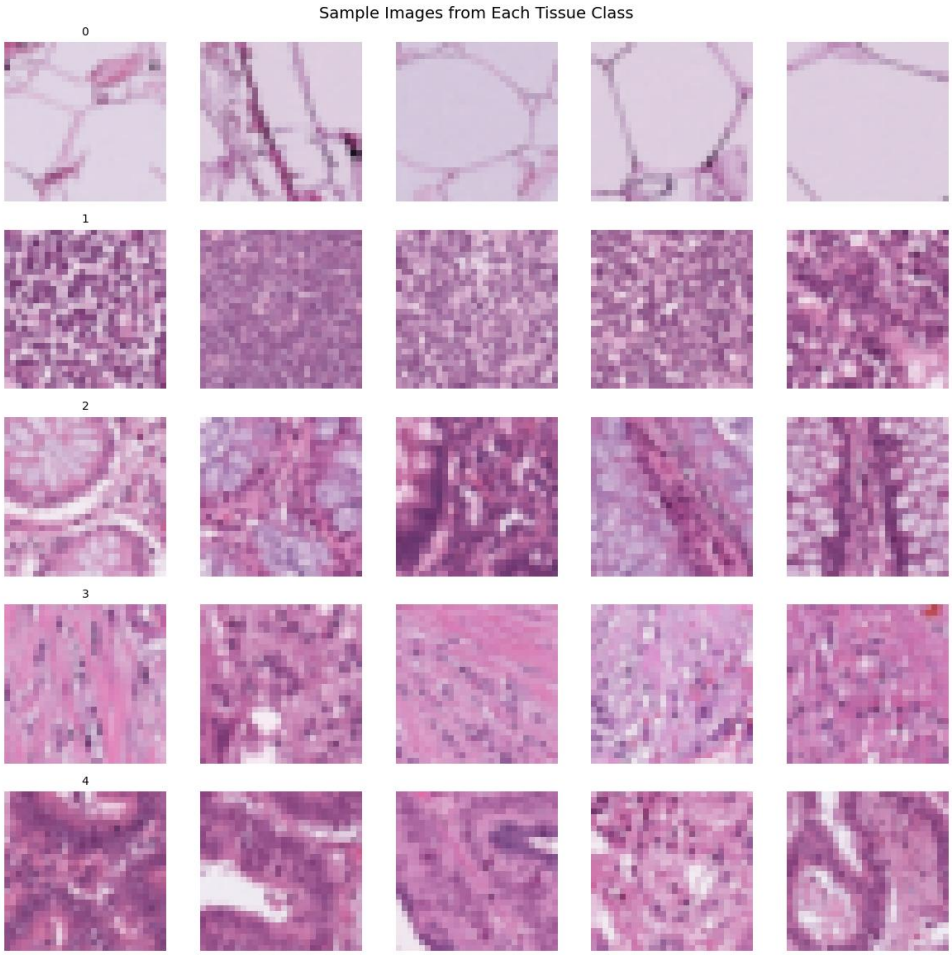

Figure 1. Sample images from each of the five tissue classes in the training set.

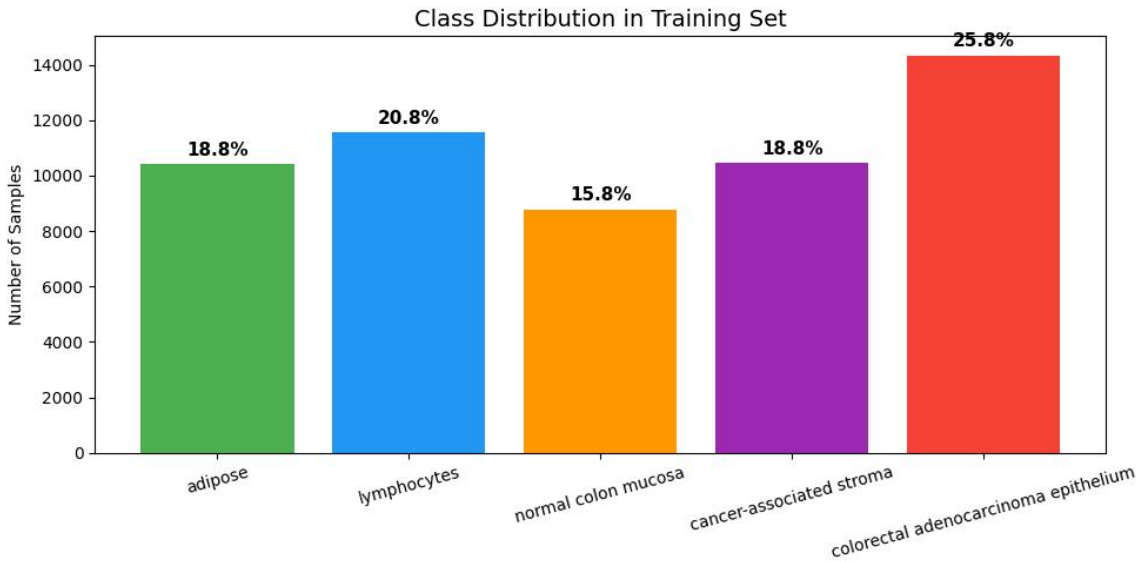

Figure 2. Class distribution in the training set showing moderate imbalance across five tissue types.

Pre-processing: Pixel values were normalised to [0, 1] by dividing by 255. The provided template converts images to grayscale by averaging RGB channels, but I retained all three channels because colour carries information in H&E stained tissue, eosin stains cytoplasm pink while haematoxylin stains nuclei blue. For sklearn, I flattened images from (28, 28, 3) to 2,352 dimensional vectors. The stratified 80/20 train/validation split also preserved class proportions. The test set wasn't touched until final evaluation.

Baseline classifier: I trained a Logistic Regression model as the required baseline using a StandardScaler pipeline with max_iter=5,000 to ensure proper training coverage. I also added a Random Forest model (100 trees) to test whether a non-linear ensemble might improve the linear baseline on flattened image features.

CNN architecture: The template CNN from canvas used just one input channel (grayscale), two convolutional layers, and incorrectly outputs nine classes. I then redesigned it with three input channels (RGB), three convolutional blocks (32→64→128 filters), following each one with batch normalisation, ReLU activation, and max-pooling. I applied Dropout (0.25) to regularize and prevent model overfitting. Two fully connected layers (1,152→256→5) map learned features to the five tissue classes.

Hyperparameter optimisation: CrossEntropyLoss was used with the Adam optimiser. I initially used a learning rate of 0.001 across 15 epochs and this produced an unstable validation loss running up and down between 0.12 and 4.97, which shows gradient overshooting. Reducing to 0.0001 with a StepLR scheduler (halving every five epochs so that my model can fine tune the details without overfitting) produced stable convergence. I trained the model for 20 epochs with batch size 64, monitoring both losses to detect overfitting.

Results

Validation set performance: The Logistic Regression achieved 70.51% accuracy on the validation set, with strong performance on adipose (F1: 0.95) but poor on normal mucosa recall (0.32). Random Forest improved to 77.19% but still achieved only 0.39 recall on normal mucosa (Figure 3). As seen from the confusion matrix, both models confused normal mucosa with cancer epithelium and stroma tissue types sharing similar structural patterns because spatial information is lost through flattening. The CNN achieved 97.13% validation

accuracy with F1 scores above 0.95 across all classes, demonstrating that convolutional layers took care of the confusion between structurally similar tissues.

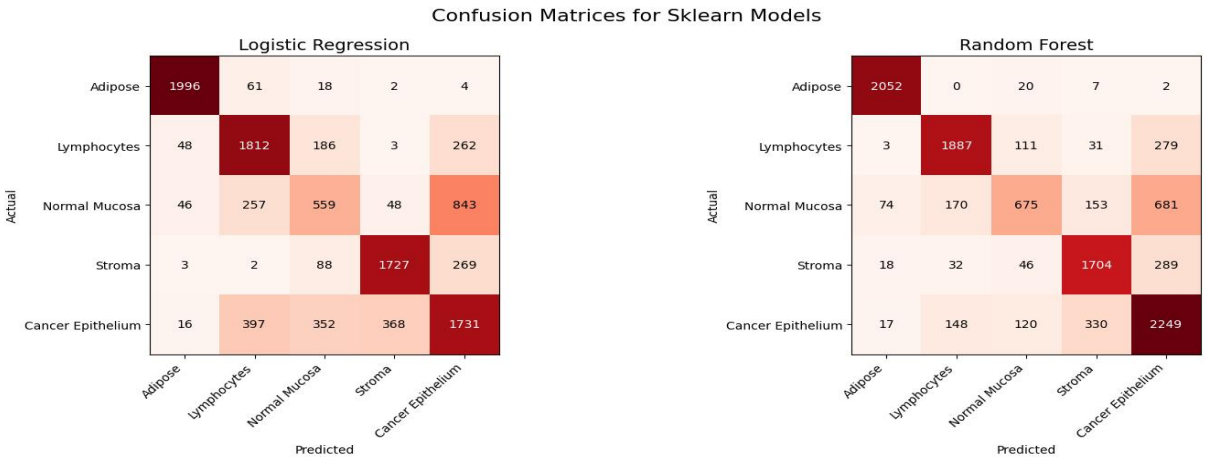

Figure 3. *Validation set confusion matrices for Logistic Regression and Random Forest.*

Evidence of correct training: Figure 4 shows CNN learning curves over 20 epochs. Both the training and validation loss decrease smoothly without divergence, confirming a progressive learning without overfitting. The StepLR scheduler is visible as we can see slight drops across epochs 5, 10, and 15. Validation accuracy stabilized around 97% by epoch 16, indicating convergence.

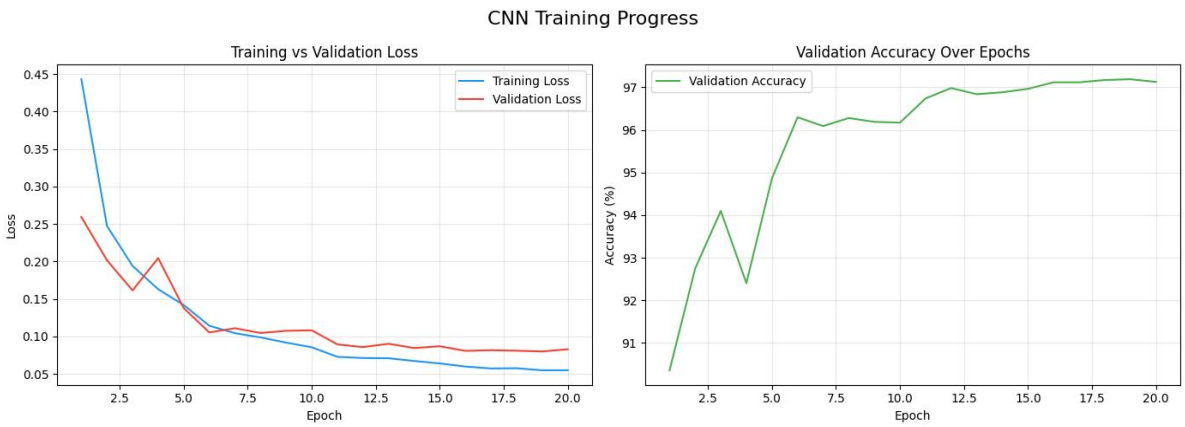

Figure 4. *CNN training/validation loss (left) and validation accuracy (right) over 20 epochs.*

Test set performance: All models were evaluated on the test set neither of them had seen before (Table 1). Logistic Regression dropped from 70.51% to 67.28% and Random Forest from 77.19% to 67.67%, while the CNN decreased from 97.13% to 93.36%. The sklearn models had larger relative drops because they rely on surface level pixel patterns that are poorly transferred when the condition of images change. The CNN retained high performance because convolutional layers learn structural features like edges, textures, and spatial arrangements that generalise across tissue locations.

Table 1. Final test set results for all three classifiers.

Model	Test Accuracy	Macro F1
Logistic Regression	67.28%	0.63
Random Forest	67.67%	0.61
CNN	93.36%	0.92

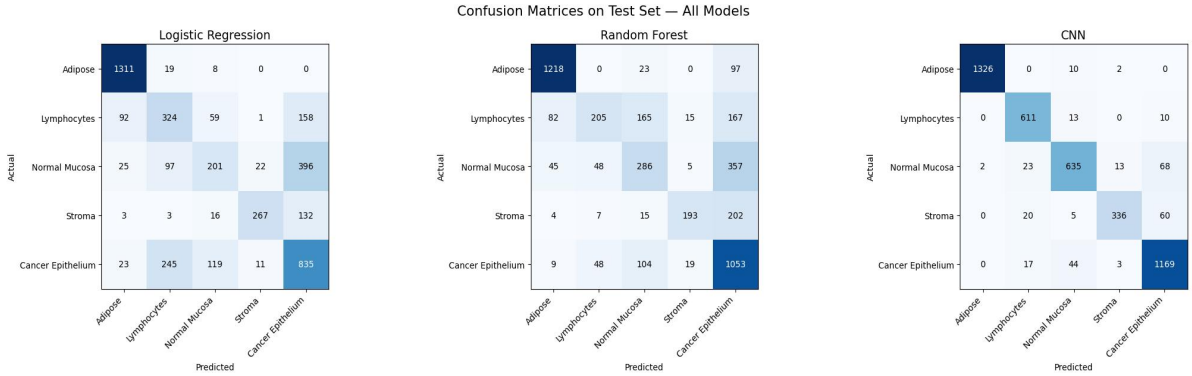

Figure 5. Test set confusion matrices for all three models.

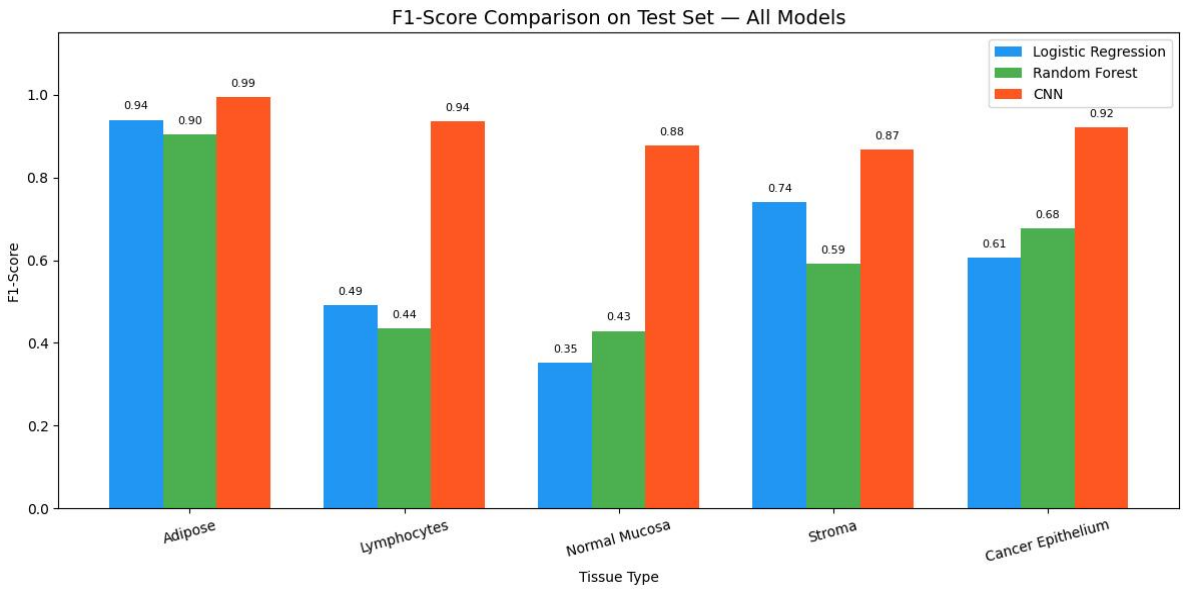

Figure 6. Per-class F1-score comparison on the test set. F1 balances precision and recall, providing a fairer metric given class imbalance.

Discussion

The CNN significantly outperformed both traditional classifiers reaching 93.36% test accuracy against the 67.28% (Logistic Regression) and 67.67% (Random Forest). The gap is most obvious for normal mucosa and cancer epithelium, which are the classes with greatest clinical significance. Logistic Regression achieved only 0.27 recall on normal mucosa, meaning nearly three quarters of normal tissue was misclassified, whereas the CNN achieved 0.86.

The first limitation of sklearn approaches is that flattening destroys the spatial relationships between pixels. Tissue classification depends strongly on structural patterns of cell arrangements, glandular shapes, and stroma-epithelium relationships and none of these can be captured from isolated pixel values. The CNN preserves these through convolutional filters that learn local patterns and build higher-level representations. The inclusion of an additional

model from my end (Random Forest) strengthens this conclusion that even a powerful non-linear ensemble cannot compensate for the lost spatial information. This confirms that the gap is due to representation rather than model complexity and efficiency.

Limitations: The low resolution (28×28) may hinder the CNN's ability to learn fine-grained cellular features. No data augmentation was applied, which could further improve generalisation. The CNN still occasionally confuses stroma with cancer epithelium, which is expected because cancer-associated stroma grows adjacent to tumour tissue and shares visual features even for expert pathologists (Kather et al., 2016).

.

References

Kather, J.N., et al. (2016). *Multi-class texture analysis in colorectal cancer histology.* Scientific Reports, 6, 27988.

Yang, J., et al. (2023). MedMNIST v2: A large-scale lightweight benchmark for 2D and 3D biomedical image classification. Scientific Data, 10(1), 41.